

AO
 AO Trauma Webinar—Periprosthetic Fractures
 —Around knee
 —Around hip

Naofumi Shiota
 Okayama Medical Center
 Japan



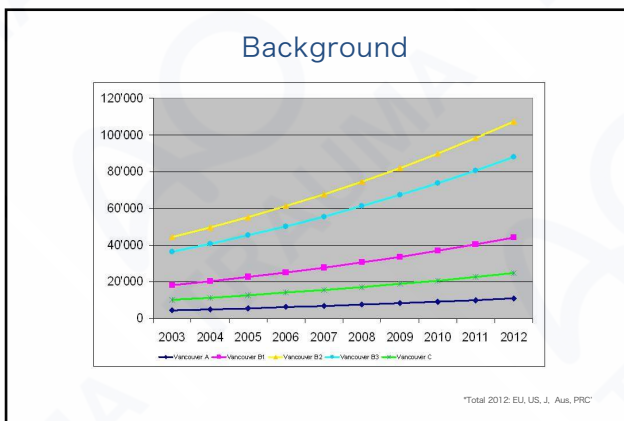
AO Trauma Webinar
 July 24, 2020

1

Learning objectives

- ▶ 既存インプラントのゆるみの評価方法とその限界について知る
- ▶ インプラント周囲骨折のX線学的診断・分類ができる
- ▶ 骨接合術・インプラント再置換術の選択を含めた治療方針を説明できる
- ▶ 内固定方法のPitfallを説明できる

2



3

Background

発生要因

- 人工関節症例 ↑
- 高齢化 → 著明な骨粗鬆症
- 活動的な高齢者 ↑
- 人工関節の長期設置や revision 症例 ↑

4

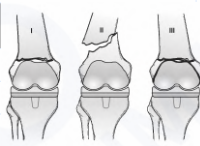
Classification for peri-TKA fractures femur

DiGioia and Rubash (1991)

Group I	Extra-articular, non-displaced (<5 mm and/or <5 degrees angulation)
Group II	Extra-articular, displaced (>5 mm and/or >5 degrees angulation)
Group III	Loss of cortical contact or angulated (10 degrees); may have intercondylar or T-shaped component

Lewis and Rorabeck Classification (1997)

Type I	Nondisplaced; component intact
Type II	Displaced; component intact
Type III	Displaced; component loose or failing

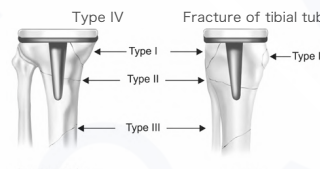


5

Classification for peri-TKA fractures tibia

Felix Classification Clin. Orthop. 1997. Vol. 345

Type I	Fracture of tibial plateau
Type II	Fracture adjacent to tibial stem
Type III	Fracture of tibial shaft, distal to component
Type IV	Fracture of tibial tubercle



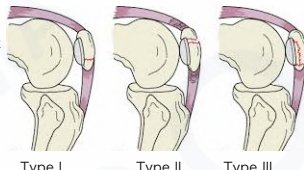
6

Classification for peri-TKA fractures patellar

Ortiguera & Berry classification JBJS 2002;84: 532-

Type I Implant/Extensor mechanism intact
 Type II Implant intact/ Extensor mechanism disrupted
 Type III Implant loose

III A : Good remaining bone stock
 III B : Poor bone stock



Type I Type II Type III

7


General management principles

インプラントのゆるみなし

- Plate固定
- Relative stability

インプラントのゆるみあり

- インプラント交換
インプラントを髓内釘のように
- Plate固定も併用
十分な固定力が得られない
インプラント側の骨も元のままでない



8

General management principles


インプラントのゆるみなし

- Plate固定
- Relative stability

インプラントのゆるみあり

- インプラント交換
インプラントを髓内釘のように
- Plate固定も併用
十分な固定力が得られない
インプラント側の骨も元のままでない

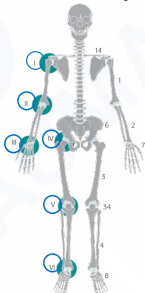
Vancouver分類



9

Diagnosis and classification

“Unified” or “comprehensive” classification system*
for all periprosthetic fractures



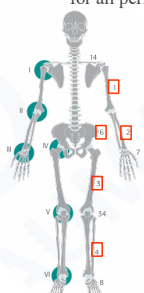
Joints:	Bones:	Types:
I shoulder		
II elbow		
III wrist		
IV hip		
V knee		
VI ankle		

*Duncan, Haddad, Perka, Schütz 2012

10

Diagnosis and classification

“Unified” or “comprehensive” classification system*
for all periprosthetic fractures



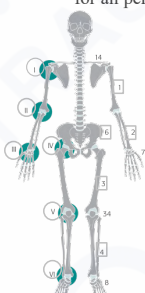
Joints:	Bones:	Types:
I shoulder	AO/OTA	
II elbow	Classification	
III wrist		
IV hip		
V knee		
VI ankle		

*Duncan, Haddad, Perka, Schütz 2012

11

Diagnosis and classification

“Unified” or “comprehensive” classification system*
for all periprosthetic fractures



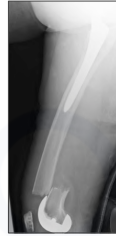Joints:	Bones:	Types:
I shoulder	AO/OTA	A-F
II elbow	Classification	“Vancouver”
III wrist		
IV hip		
V knee		
VI ankle		

*Duncan, Haddad, Perka, Schütz 2012

12

Type	
A Apophyseal or extraarticular/ periarticular	A1 Avulsion of A2 Fracture of
B Bed of the implant or around the implant	B1 Prosthesis stable, good bone B2 Prosthesis loose, good bone B3 Prosthesis loose, poor bone or bone defect
C Clear of or distant to the implant	-
D Dividing the bone between two im- plants or interprosthetic or intercalary	-
E Each of two bones supporting one arthroplasty or polyarthroplasty	-
F Facing and articulating with a hemiar- throplasty	-

Vancouver分類

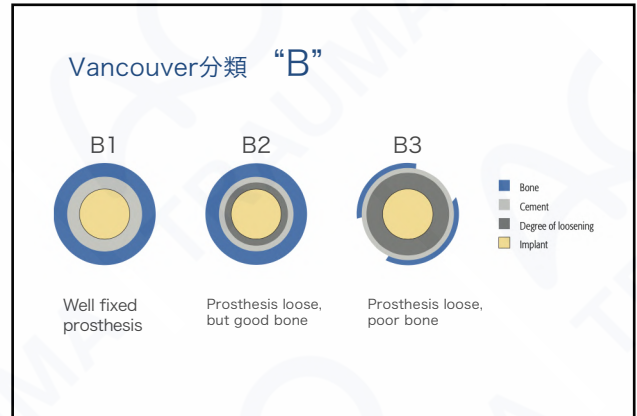


インプラント間骨折

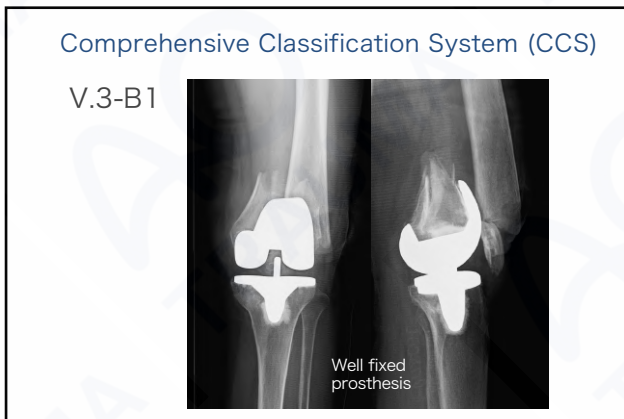
インプラント両側骨折

HAP反対側骨折

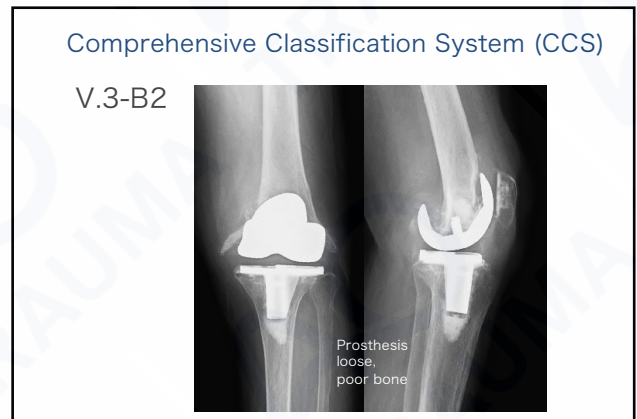
13



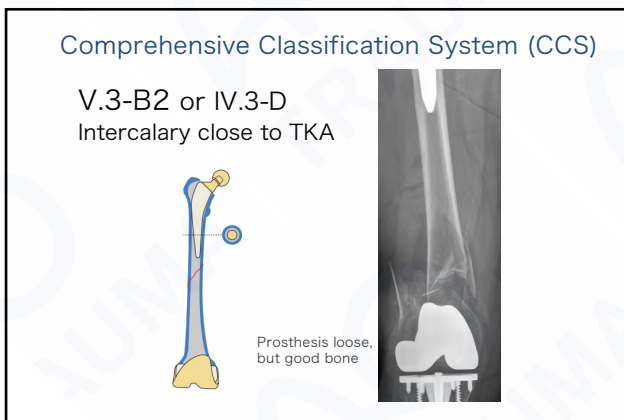
14



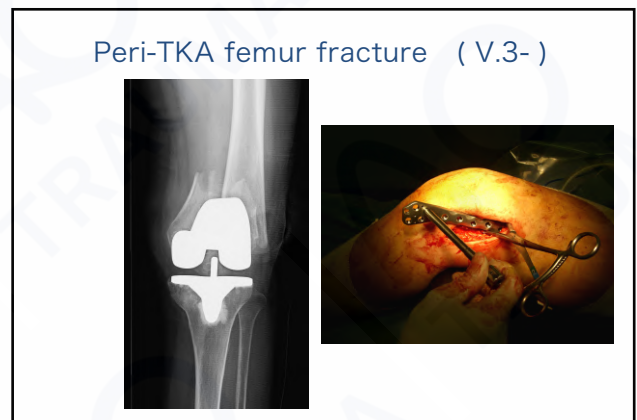15



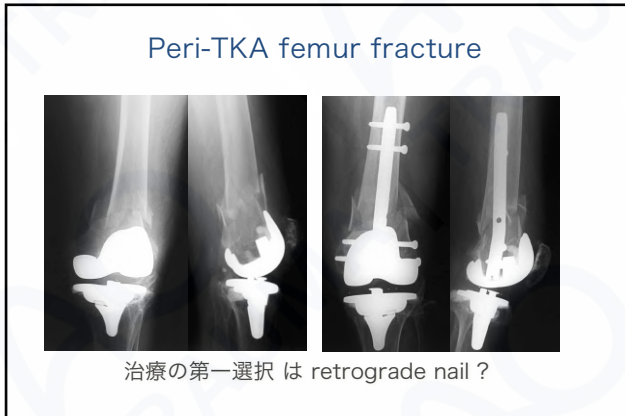
16



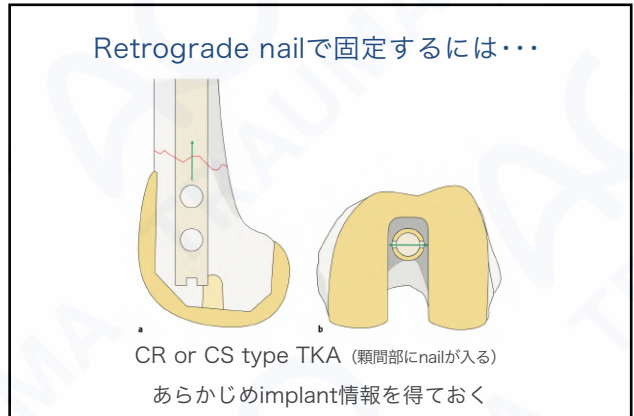
17



18



19



20

Equivalent union rates between intramedullary nail and locked plate fixation for distal femur periprosthetic fractures – a systematic review

Shah et al. Injury 2020

Variables	LCP	IMN
Patients (n)	919	269
Union percent (%)	93.6	91.7
Time to union (weeks)	17.1	18.7
Complication rate (%)	17.2	22.9
Reoperation rate (%)	9.6	14.6
Full weightbearing (%)	94	100
Time to full weight bearing (weeks)	15.8	7.6
Return to preinjury activity (%)	61.6	70.8

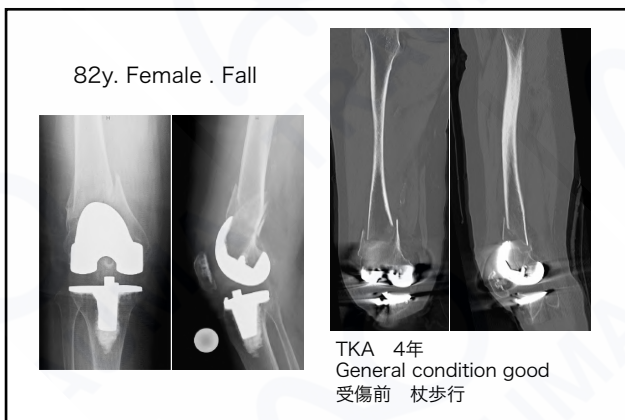
21

Equivalent union rates between intramedullary nail and locked plate fixation for distal femur periprosthetic fractures – a systematic review

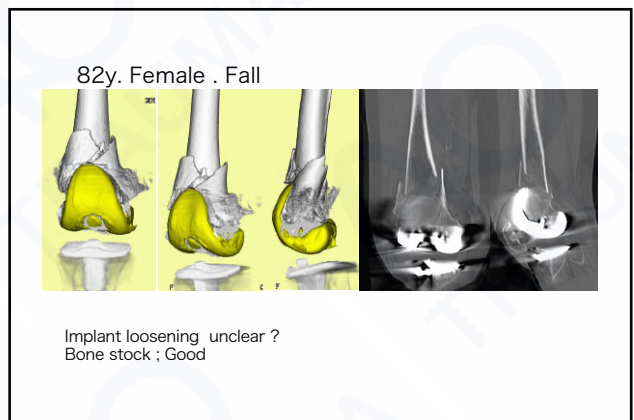
Shah et al. Injury 2020

Complication list	LCP	IMN
Hardware Failure	46 (5.0)	17 (6.3)
Painful Hardware	9 (0.98)	5 (1.9)
Infection (superficial)	12 (1.3)	3 (1.1)
Infection (deep)	20 (2.2)	1 (0.37)
Peri-implant fracture	4 (0.44)	5 (1.9)
Malunion	23 (2.5)	31 (11.5)
Delayed Union	15 (1.6)	0 (0)
Pulmonary Embolus	2 (0.22)	1 (0.37)

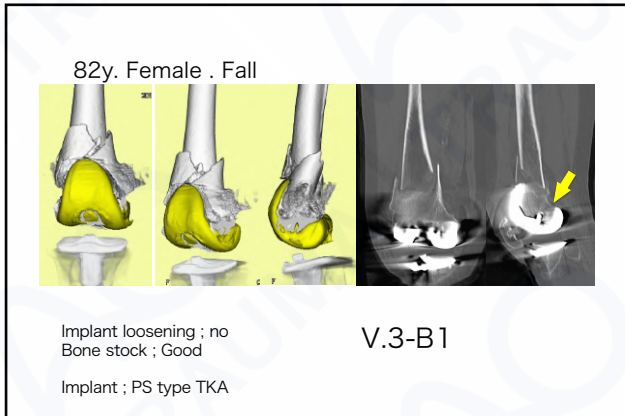
22



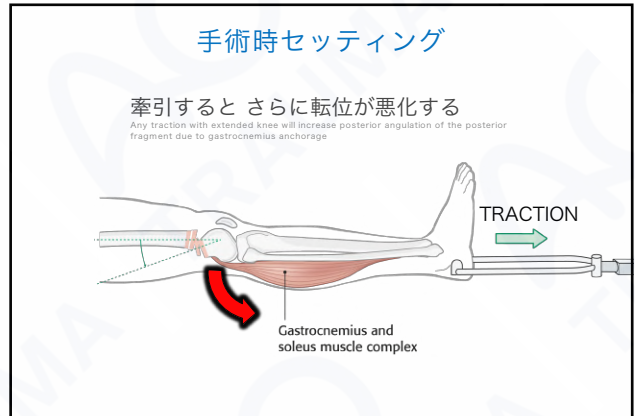
23



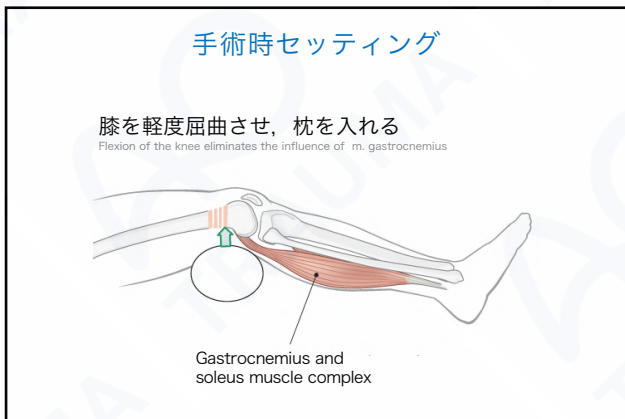
24



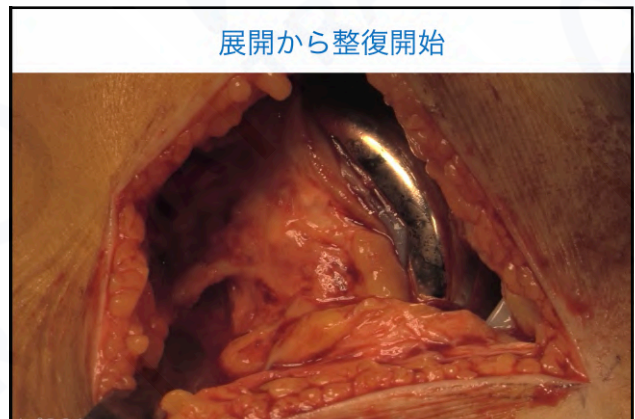25



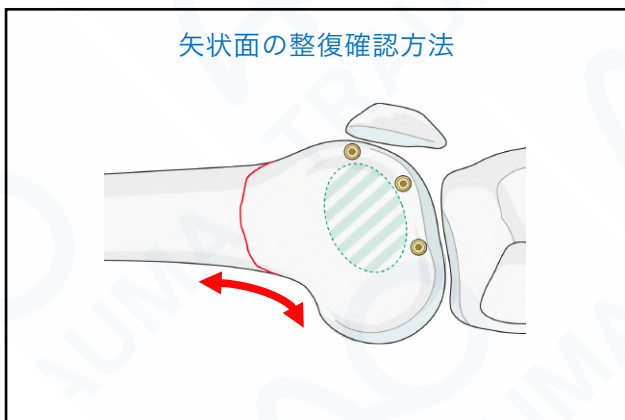
26



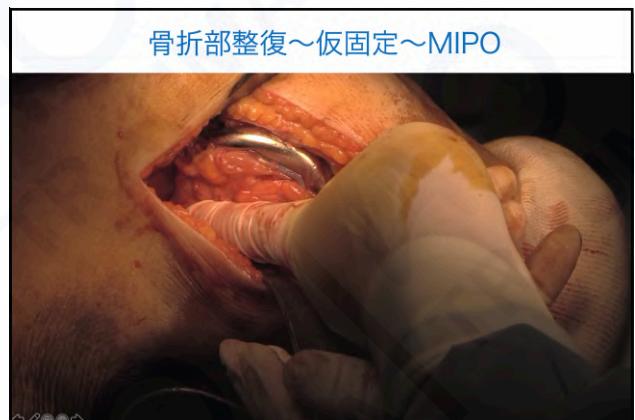27



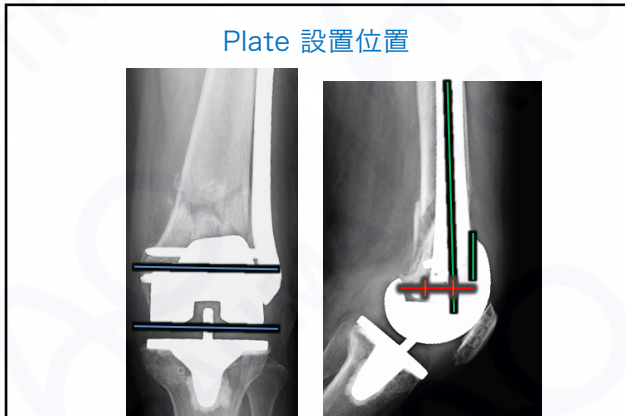
28



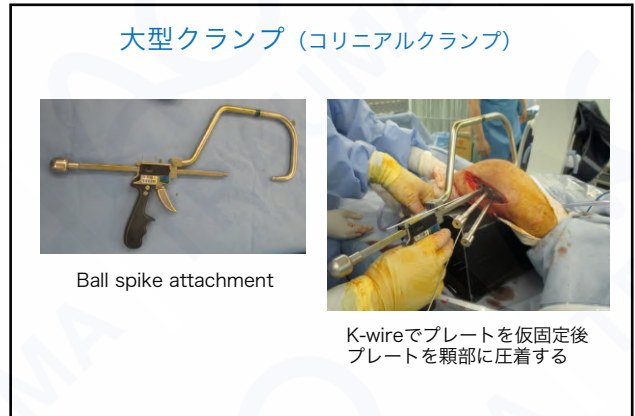29



30



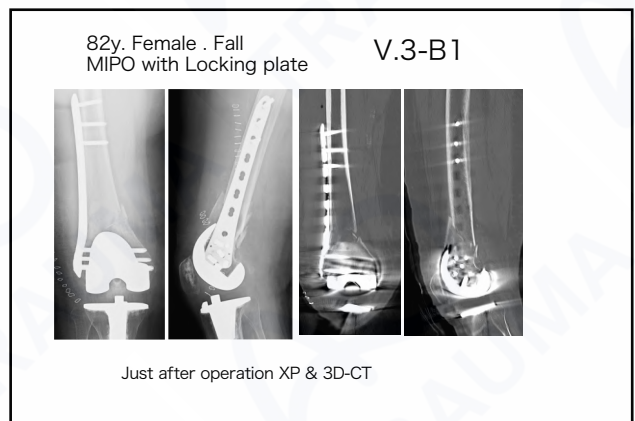
31



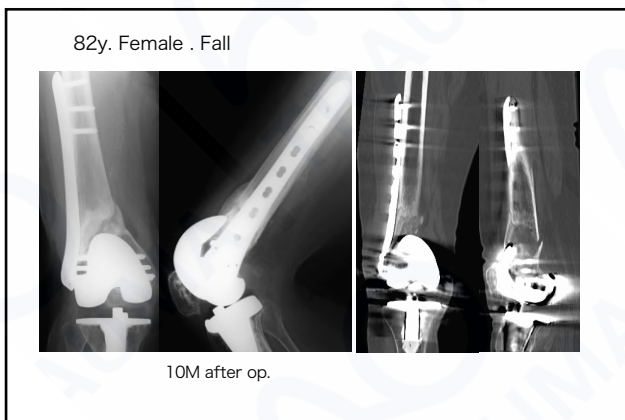
32



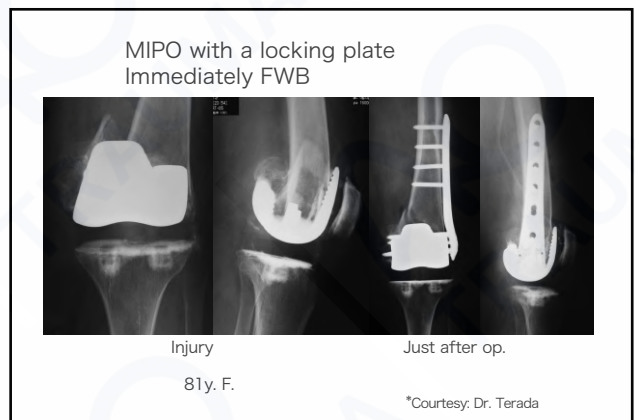
33



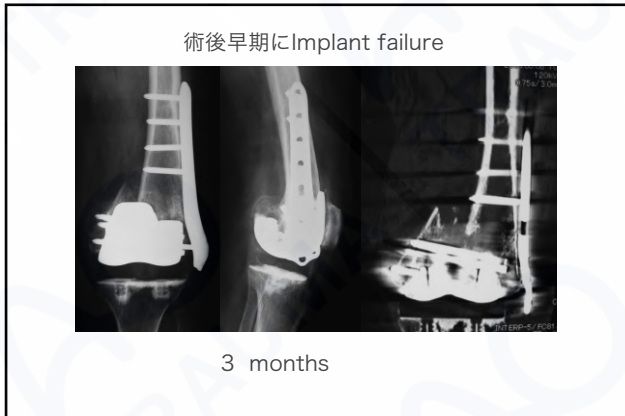
34



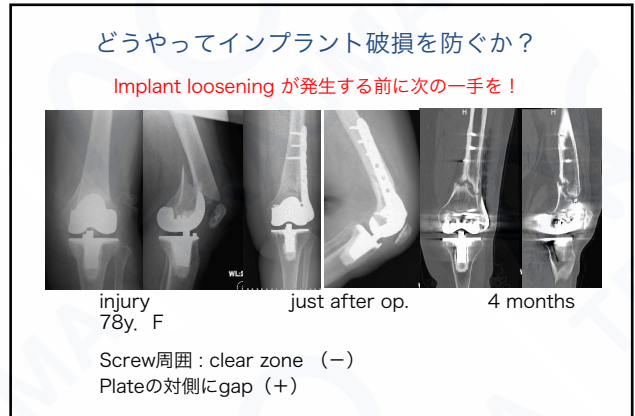
35



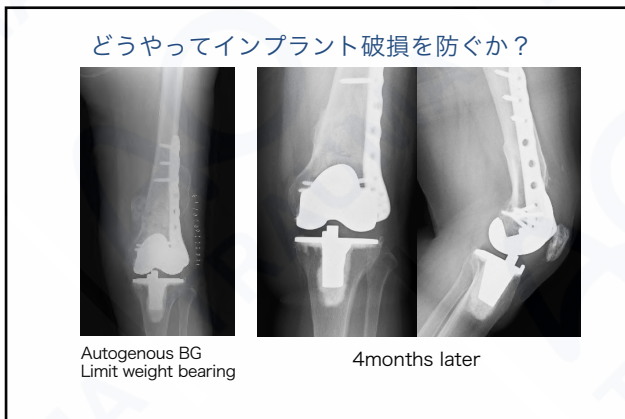
36



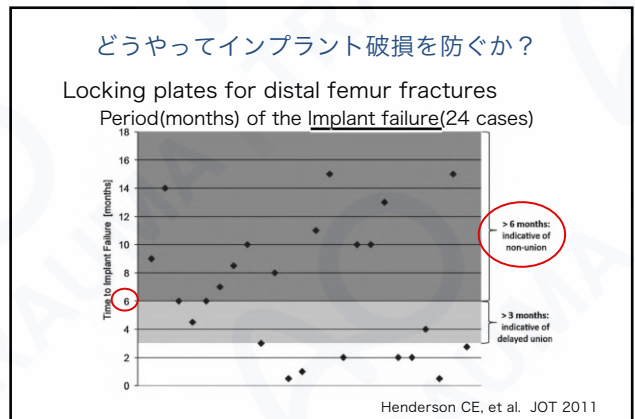
37



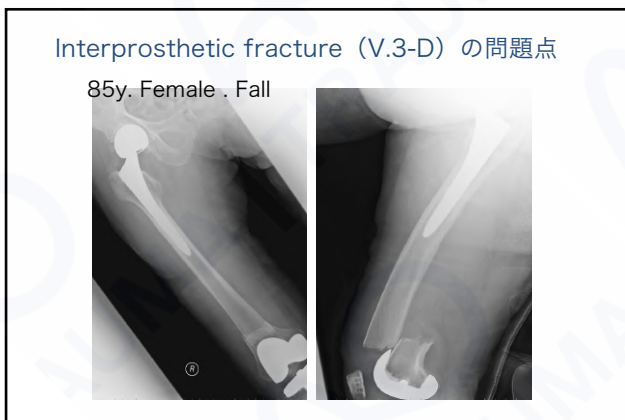
38



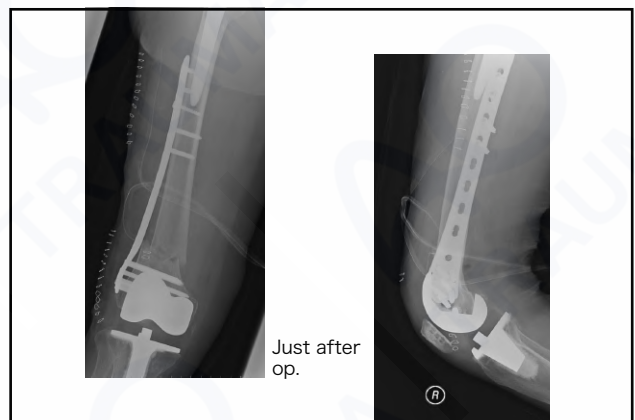
39



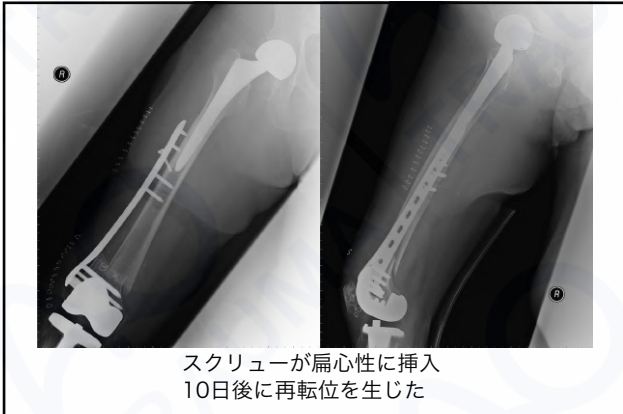40



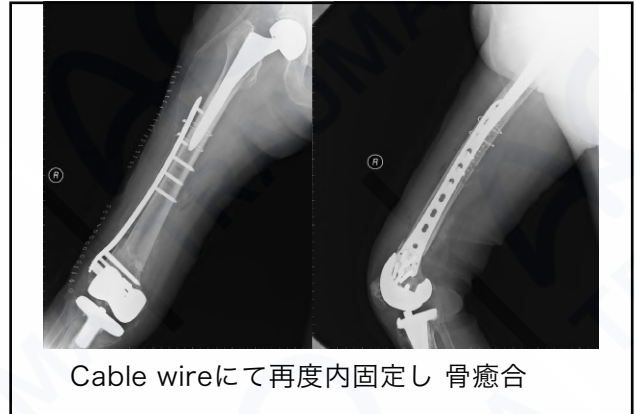
41



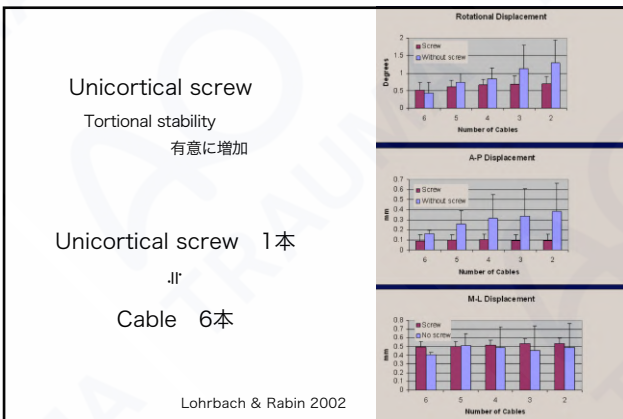
42



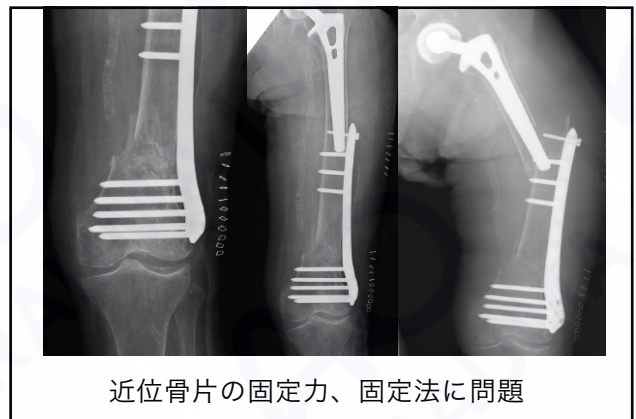
43



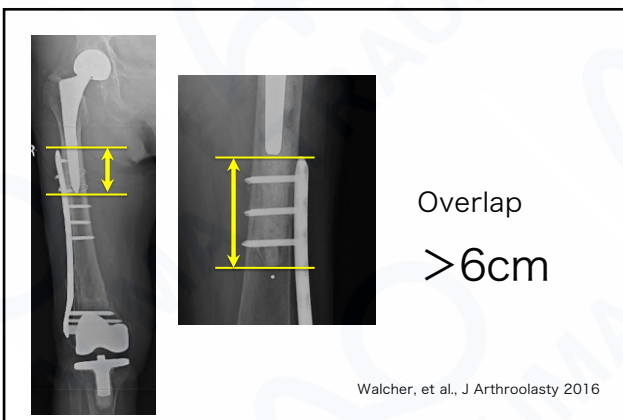
44



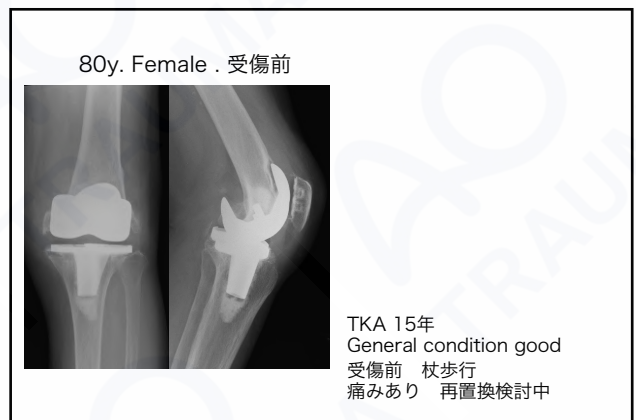
45



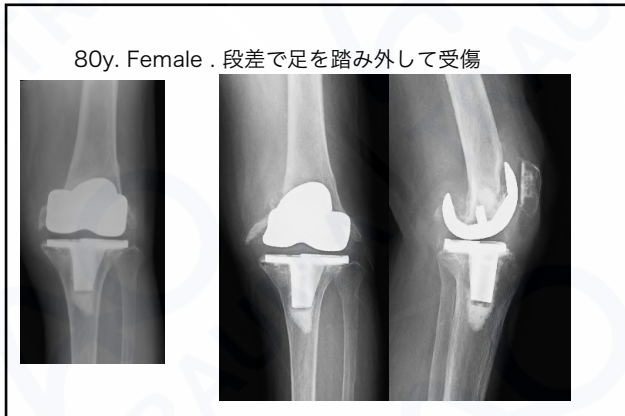
46



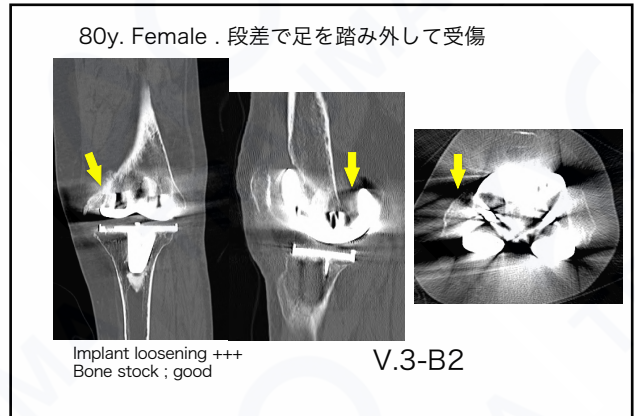
47



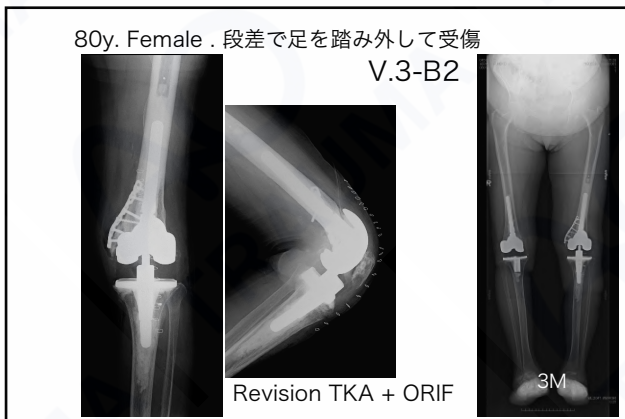
48



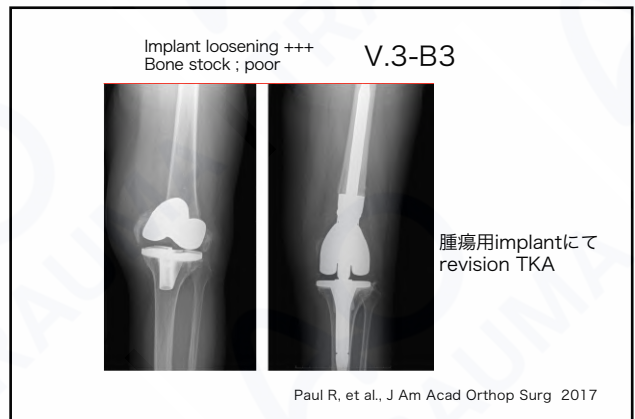
49



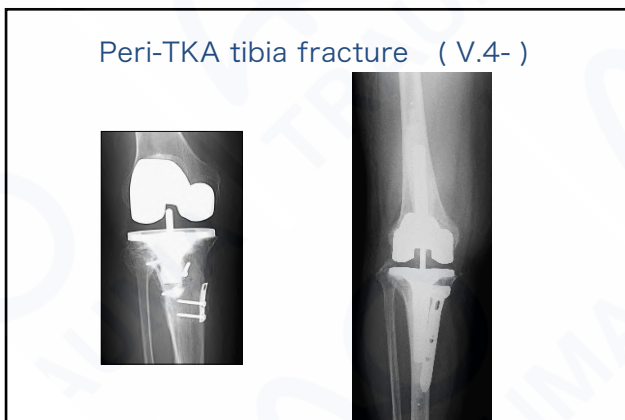
50



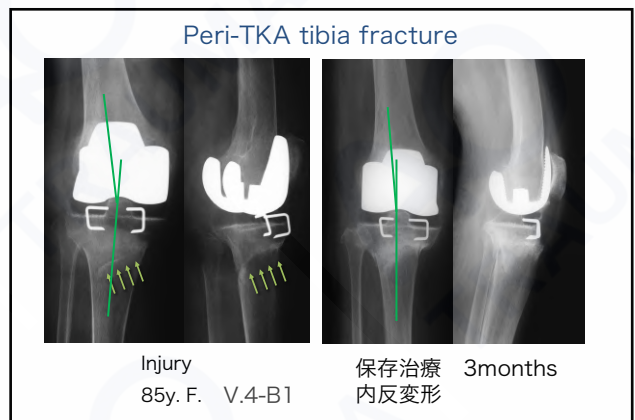
51



52



53



54

